



Medical College of Georgia

Neuroscience Outlook

Department of Neurosurgery Newsletter

Volume 3, Issue 2 - Winter 2007

Inside This Issue

Chair's Message

Department News

Researcher attains one of highest scores on NIH R01 grant

MCG Neurointensive care unit featured on national PBS special

Neuro-Oncology update

Contributor acknowledgement

Clinical Spotlight

Correction of post-surgical fixed cervical kyphotic deformity

Minimally invasive unilateral TLIF

Faculty and Staff Update

Accomplishments & Recognition

Residents'/Fellows' Corner

Contributor acknowledgement

Spine Fellowship update

Presentations/Publications

July-December 2006

Conference Schedule

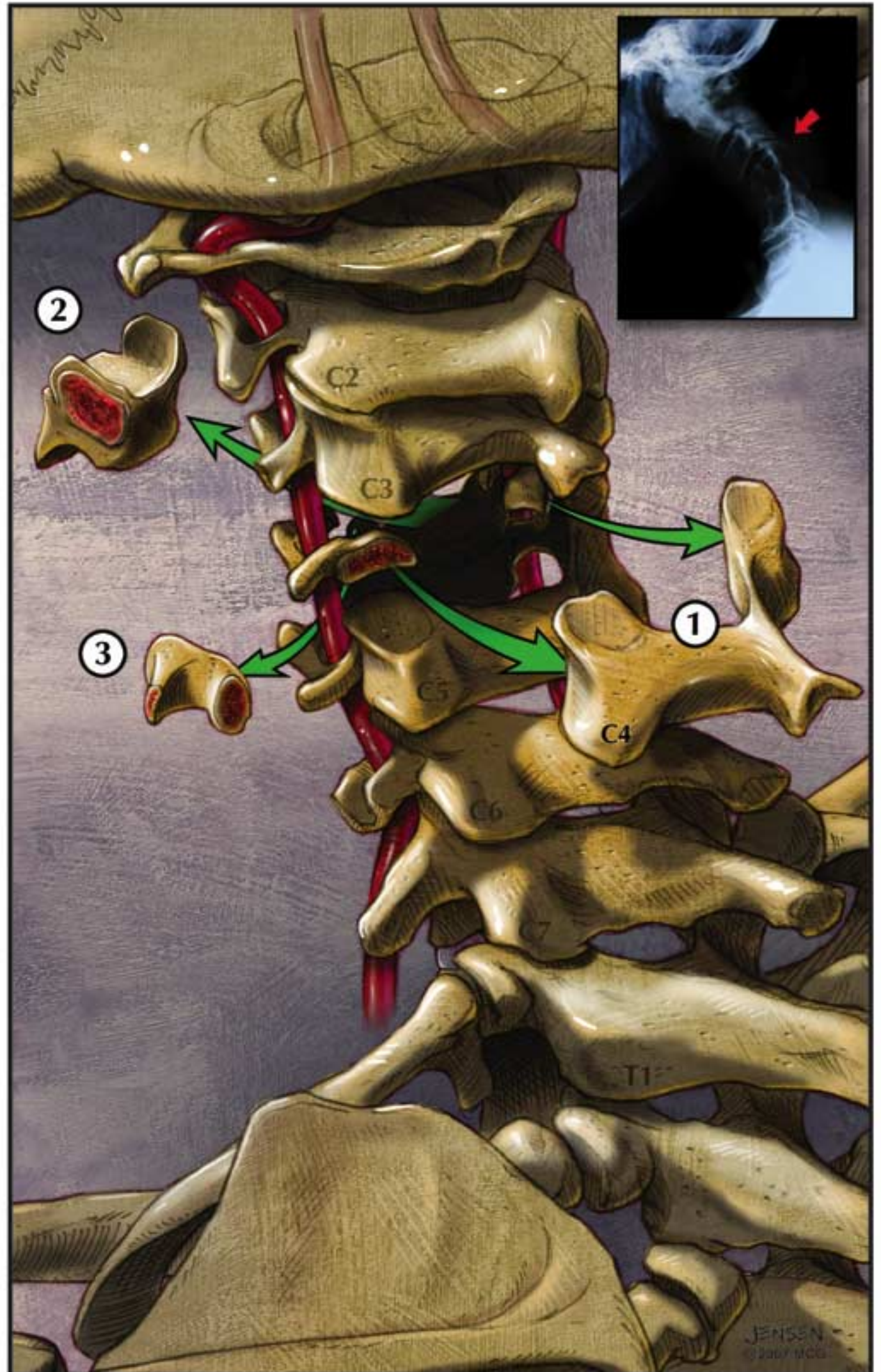
January-June 2007

Upcoming Meetings

January-June 2007

www.mcg.edu/som/neurosurgery

MCG
Neuroscience Center



Clinical Spotlight: Three-staged correction of post-surgical fixed cervical kyphotic deformity

Chair's Message

Welcome to the Winter 2007 issue of Neuroscience Outlook. We are very pleased to provide you with a current update of the Department of Neurosurgery at the Medical College of Georgia. In this issue, we highlight our Neurosurgery Spine Service directed by **Dr. Haroon Choudhri**. The Clinical Spotlight is presented by Haroon F. Choudhri, M.D. and **Walid Attia, M.B.Ch.B., Ph.D.** It features an innovative surgical correction of cervical kyphosis in Case 1, and a minimally invasive unilateral transforaminal lumbar interbody fusion for Case 2. We congratulate **Sergei Kirov, Ph.D.** for being awarded a new R01 grant for the Department of Neurosurgery, and in the process, receiving one of the highest priority scores in his NIH study section (top 1.3 percentile). The grant is entitled "*Activity and dendritic structural rearrangements in the mature brain*". Details on this grant can be read in the Department News section. Also in this section we provide an update on the ongoing Neuro-Oncology protocols under the direction of **Alfredo D. Voloschin, M.D.**, and elaborate on the PBS special "*Remaking American Medicine*" that featured our Neurointensive care unit, staff, physicians, and patients.



Dr. Mark Lee

As always, we acknowledge the generous donations to our department and highlight the research presentations and publications of our faculty. We hope you enjoy this issue.

Mark R. Lee, M.D., Ph.D., F.A.C.S.
Professor and Allen Distinguished Chair
Department of Neurosurgery

Cargill H. Alleyne, Jr., M.D.
Editor-in-Chief
Associate Professor and Academic Vice-Chair
Residency Program Director
Department of Neurosurgery

Department News

Researcher attains one of the highest scores on NIH R01 grant



Dr. Kirov at work in his lab


Sergei Kirov, Ph.D. received one of the highest scores (top 1.3 percentile) for his R01 grant application ("*Activity and dendritic structural rearrangements in the mature brain*") at the Neurodifferentiation, Plasticity, and Regeneration (NDPR) Study Section and assigned to the National Institute of Neurological Disorders and Stroke (NINDS) Repair and Plasticity Program. The exact dollar amount and grant period will be decided at the Council Review of the NINDS in February. The findings that motivate this proposal are from published papers supported by a National Institute of Mental Health (NIMH) K01 MH02000 grant together with new data from work in progress.

Briefly, the goal of the research is to elucidate the mechanisms of synapse and spine formation and maintenance of the mature brain under normal and pathological conditions. The vast majority of excitatory synapses in the adult brain occur on dendritic spines. Changes in the number of dendritic spines alter the connectivity of neuronal circuits, impacting the brain's ability to store information. Activity sculpts synaptic networks throughout the lifespan. Excessive activation during disease such as epilepsy or stroke or during traumatic brain injury results in acute dendritic swelling and spine loss leading to a profound restructuring of the brain circuitry. Reorganization of surviving synaptic networks could provide support for synaptogenesis and recovery of function.

Aims of this R01 grant are to include in vitro (murine brain slices) and in vivo mouse models to assess the role of activity of crucial neuronal structural rearrangements in the mature brain during injury arising from ischemia. In the minutes and hours following focal stroke, ischemic cortex undergoes repeated peri-infarct depolarizations (PIDs) that may expand secondary injury. Understanding these events at the cellular level may reveal new substrates for neuroprotective drugs.

MCG Neurointensive care unit featured on national PBS special

MCG Neuro-ICU and the Neurology and Neurosurgery staff, physicians and patients were featured in a segment of the PBS series "*Remaking American Medicine: Healthcare for the 21st Century*". The fourth part of the documentary series was entitled "*Hand in Hand*" and aired on October 26th, 2006. It focused on the unique patient-centered care approach that was initiated at MCG's Children's Medical Center and continued at the Neuroscience Center of Excellence.



DVD Cover of "Remaking American Medicine"

Department News *(continued...)*

Neuro-Oncology Program update

The Neuro-Oncology program continues to thrive under the leadership of **Alfredo D. Voloschin, M.D.** There are numerous clinical trials and research studies currently underway. A list of the trials and studies follows. Look for more details on individual trials in an upcoming edition of our newsletter.

- 2005 *Ribonucleases as a Pathogenic Agent of Paraneoplastic Neurologic Syndromes*. Case-Control Study. Principal Investigator: Alfredo D. Voloschin, M.D. Collaboration from NIH and UPENN. HAC (IRB) approved Status: Open.
- 2005 *Paraneoplastic Disorders of the CNS: Autoantigen Profiling*. Principal Investigator: Alfredo D. Voloschin, M.D. In collaboration with University of Pennsylvania. HAC (IRB) approved. Status: Open.
- 2005 *A Phase II Study of Liposomal Cytarabine (DepoCyt) and Temozolomide (Temodar) for Neoplastic Meningitis from Breast Carcinoma*. Multi-center trial. Principal Investigator at MCG: Alfredo D. Voloschin, M.D. IRB approved. Status: Open.
- 2006 *Temozolomide as Neoadjuvant and Chemo-radiotherapy following resection and GLIADEL® Wafer Placement in Patients with Newly*

Diagnosed High-grade Glioma. Principal Investigator at MCG: Alfredo D. Voloschin, M.D. IRB approved. Status: Open.

- 2006 *Evaluation of T-cell Immunity with Paraneoplastic Neurologic Disorders*. Principal Investigator: Alfredo D. Voloschin, M.D. In collaboration with University of Pennsylvania. HAC (IRB) approved as addendum to Autoantigen Profiling Protocol. Status: Open.
- 2006 *Phase V Gliaste Radiation Therapy System Registry Protocol for the Treatment of Resectable Malignant Brain Tumors*. PI: John Vender, MD. Sub-Investigator: Alfredo Voloschin, MD. HAC approved.
- 2006 *Human GBM cell line U87MG treated with Sera and CSF from Patients with and without Paraneoplastic Neurologic Syndromes*. Principal Investigator: Alfredo D. Voloschin, MD in collaboration from Dr. R. Yu and Dr. G. Zeng from the Institute of Molecular Medicine and Genetics (IMMAG). HAC (IRB) and IACUC: approved. Status: Open.
- 2006 *Glioblastoma Multiforme Animal Model: Potential Neurotoxicity and anti-tumor effects of Sera and CSF from Patients with and without Paraneoplastic Neurologic Syndromes*. Principal Investigator: Alfredo D. Voloschin, MD in collaboration from Dr. R. Yu and Dr. G. Zeng from the Institute of Molecular Medicine and Genetics (IMMAG). HAC (IRB) and IACUC: approved. Status: Open.

Contributor acknowledgement

We appreciate the generous donations to the department from **Dr. and Mrs. Marshall Allen** (\$1000), **Pfizer** (\$1000), and **Gene Stalcup** (\$2000). See the Residents' and Fellows' corner for acknowledgement of donations to the resident education.

Faculty Update

Accomplishments and Recognition

Sergei A. Kirov, Ph.D. has received one of the highest scores for his R01 grant submission. See Department News (pg.2) for details.

John R. Vender, M.D. is the president-elect of the Georgia Neurosurgical Society. He also serves on the Congress of Neurological Surgeons' Certification Committee and the Education Committee.

Cargill H. Alleyne, Jr., M.D. is one of the founding members of the Society of Endovascular Neurosurgeons. He is also serves on the Congress of Neurological Surgeons' Fellowship Committee and the Abstract Grading Committee of the International Stroke Conference, February 2007.

Residents' and Fellows' Corner

Contributor acknowledgement

From July to December of 2006 we were fortunate to receive monetary donations, reimbursement for resident travel and a book donation from external sources. They include:

- A donation of \$650 from **Crosslink Orthopedics** to the resident education fund.
- Reimbursement of \$1071 from **Synthes spine** to partially fund resident travel to the Armed Forces Institute of Pathology course and \$1156 to fund resident travel to a 3-D surgical anatomy course.
- A donation of the fifth edition of the Schmidek and Sweet's *Operative Neurosurgical Techniques* from **UCB Pharma**.

We sincerely thank each of these companies for their generous donations.

Spine Fellowship update

We welcomed **Walid Attia, M.B.Ch.B., Ph.D.** to the spine fellowship program in October 2006. Dr. Attia completed his medical training in Tanta, Egypt and his neurosurgical training in Matsumoto, Japan.

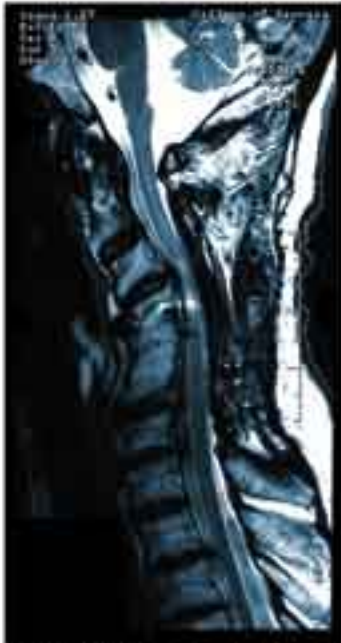For more information on MCG's Spine Program, visit:



Dr. Walid Attia

Clinical Spotlight: Case 1

Three-staged correction of post-surgical fixed cervical kyphotic deformity



Sagittal MRI shows compromise at spinal level C4.

Clinical Features

One of the late complications of cervical spinal surgery is iatrogenic kyphosis. Anterior column shrinkage and compromise of the posterior element tension band may contribute to the loss of lordosis. The primary technical contributors to this problem are undersized anterior strut grafts, aggressive laminectomy/facetectomy without posterior instrumentation and settling of anterior constructs, particularly when plating is not used. Patients who develop kyphosis may develop accelerated progression of their spondylosis, and deformity correction may be considered as part of any therapeutic intervention. This correction may also prevent future deterioration of the remaining motion segments.

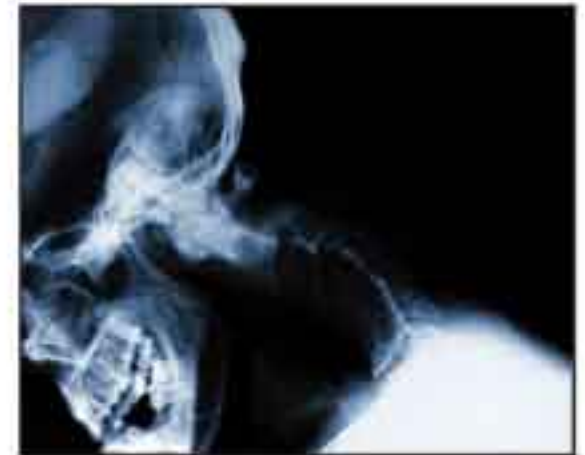Surgical Planning

Plain film radiographs, especially flexion/extension dynamic images are valuable in the surgical planning when deformity exists. In patients with flexible curves, the majority or all of their sagittal imbalance can be corrected. These patients can be positioned for surgery in the desired final alignment and held in situ with internal fixation. Anterior-posterior fixation may be required in some cases where the deformity correction is significant or when the pathology to be addressed cannot be adequately treated via a single

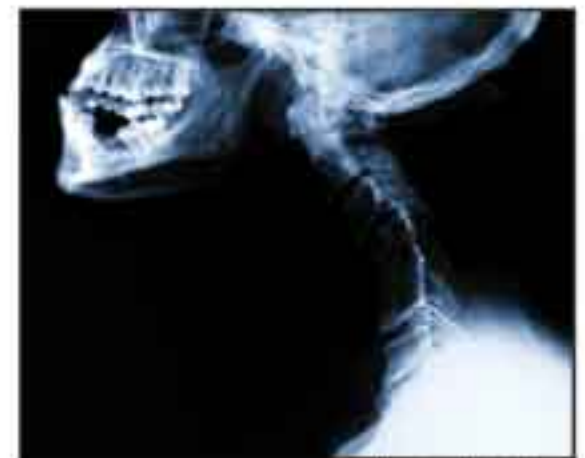approach. Patients who cannot be reduced on dynamic radiographs have a fixed deformity. Correction of a fixed deformity typically requires sequential posterior osteotomies, anterior releases and reconstruction with internal fixation in three stages.

Case Presentation

The patient is a 62-year-old man who underwent an anterior cervical discectomy and fusion (ACDF) on two occasions at the C4-5 and C5-6 levels in the early 1980s. No anterior instrumentation was used. He developed progressive symptoms and was treated with wide laminectomies from C2 to C7. He did reasonably well for 18 years and now presents with a fixed kyphotic deformity with rapidly progressive myelopathy manifesting as gait deterioration and loss of fine motor skills in his hands. He also complains of severe neck pain associated with any change in neck position, cannot raise his head, and lifts his chin with his arms to look forward. Plain films demonstrate a solid fusion from C4 to C6 with kyphotic angulation that does not correct significantly in extension. An MRI demonstrates severe attenuation of the cervical spinal cord as it drapes over the ventral compressive elements.

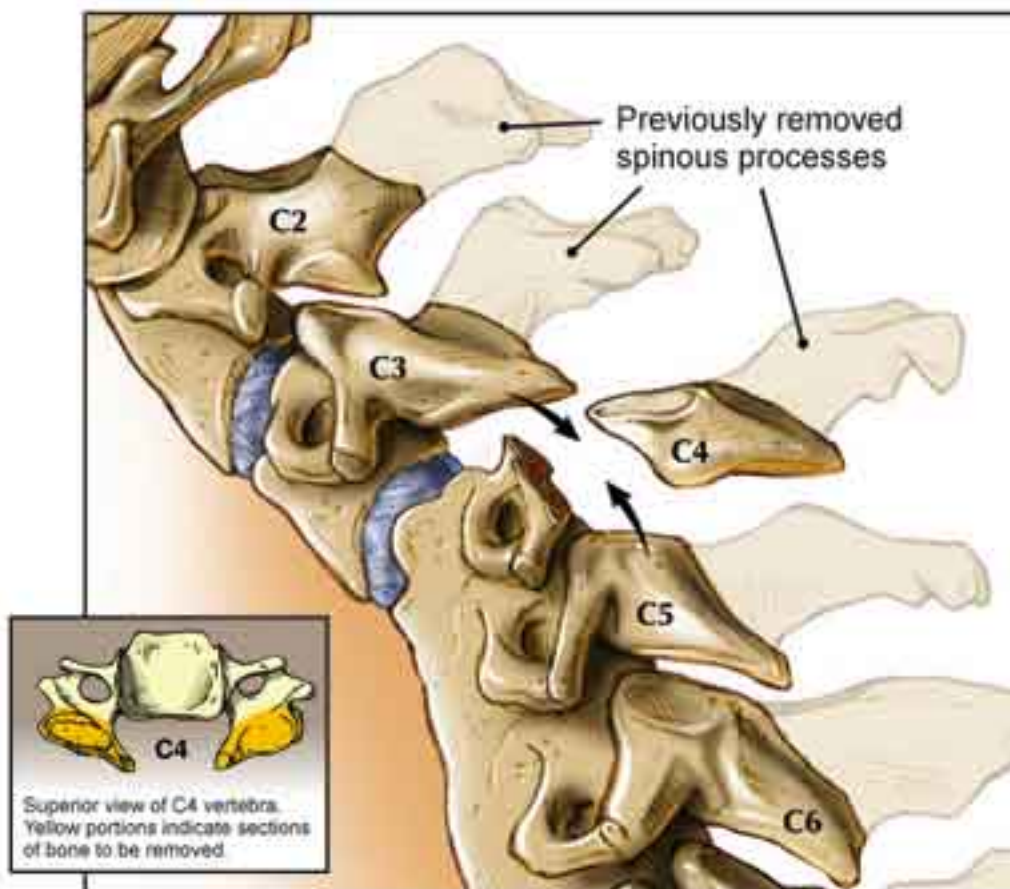


Pre-op: Flexion



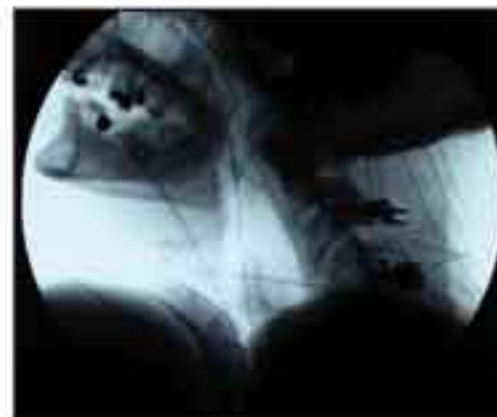Pre-op: Extension

The surgical treatment of this patient involved three stages. An animated film segment of this surgical plan is available at www.complexspinesurgery.net/movies

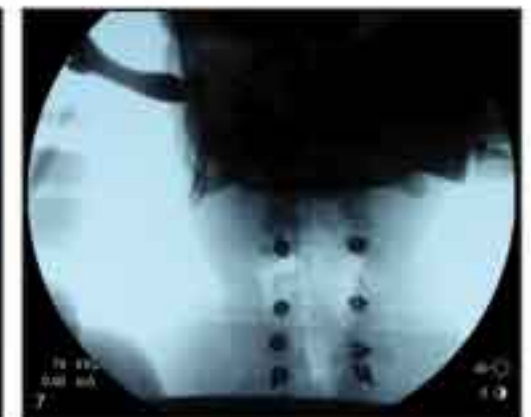

Stage 1 - Posterior osteotomies & screw placement without rods

Complete removal of the lateral masses of C4 will allow the inferior facets of C3 to migrate posteriorly towards the C5 lateral masses. Rod placement at this time would prevent correction of the deformity during the second stage (anterior releases). Although the screws may also be placed with the rods at Stage 3, it is the authors' preference to place the screws without rods at the first stage. This allows for CT



Sagittal fluoroscopic image shows proper posterior placement of screws following Stage 1 surgery.



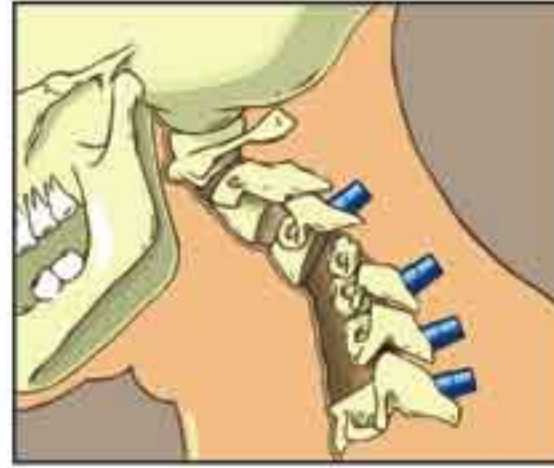AP view of bilaterally-placed screws in cervical vertebrae following Stage 1 surgery.

Clinical Spotlight: Case 1 (continued...)

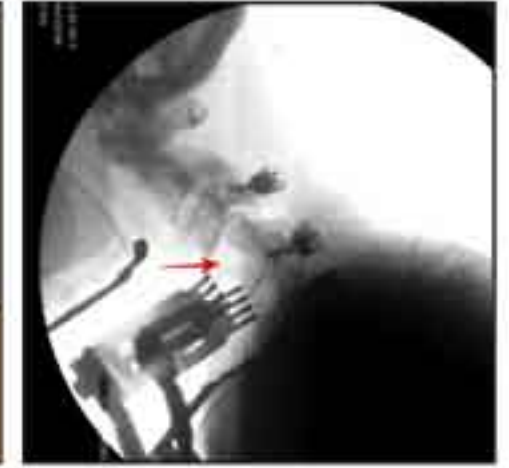scanning between stages to guide any repositioning which may be required and minimizes the operative time for the third stage.

Stage 2 - Anterior releases with C4-6 corpectomies and deformity correction with anterior strut graft and plate

Complete decompression of the ventral spondylosis with resection of the posterior longitudinal ligaments is performed via multilevel corpectomies. The patient is positioned supine with the head fixed in a 3-point Mayfield head clamp to prevent undesired motion as the anterior releases are completed. The head holder is carefully released and the extent of restoration of lordosis is ascertained. In this case, anterior release required resection of the bone surrounding the transverse foramina bilaterally. Once the desired final alignment is achieved, the head holder is again secured and a wedge-shaped iliac crest allograft strut is inserted and secured with anterior plating.



Frame from animated web-film showing the cavity left from the corpectomy during Stage 2 surgery.



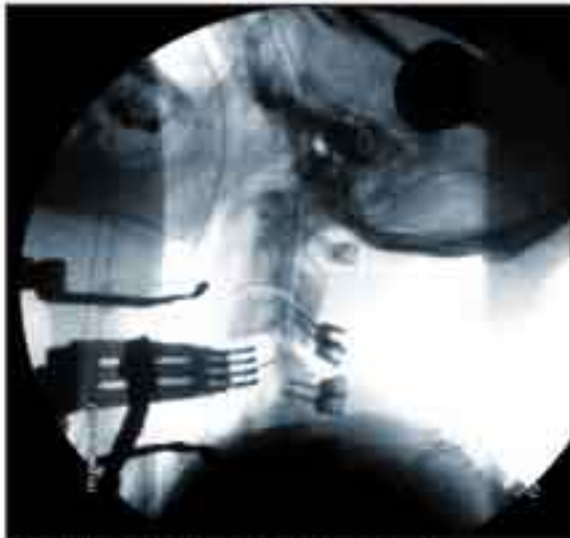
Matching fluoroscopic image, taken in mid-Stage 2 surgery, showing well-executed corpectomy.

Stage 3 - Posterior rods

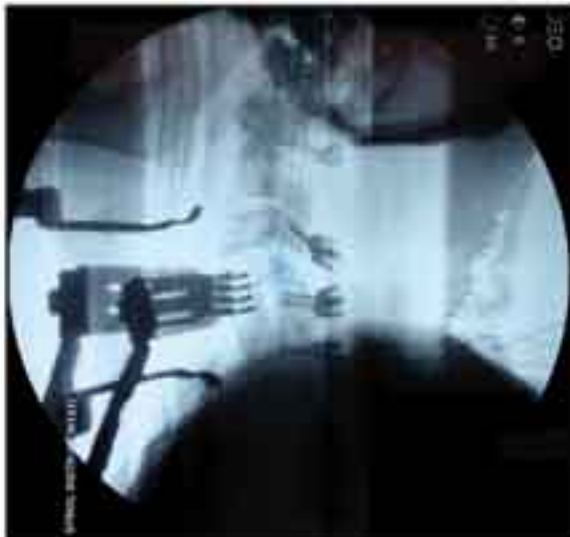Since the screws have already been placed, the third stage consists of cutting the sutures and then placing and securing the rods in the final position that has been achieved during Stage 2. Typically Stage 1 is performed on one day, and a CT scan is obtained after surgery to evaluate the screws placement. Stages 2 & 3 are performed the following day. In this case, no hardware repositioning was required.

The patient did well after surgery with only transient swallowing difficulties. At the three-month follow-up visit he had significant improvement in his mechanical neck pain and ability to look forward. His gait and fine motor skills improved significantly. Plain films show that his alignment has been maintained.

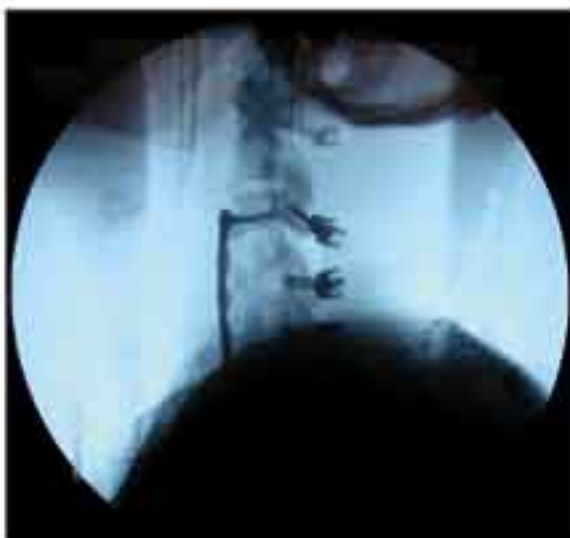(Haroon F. Choudhri, M.D. and Walid Attia, M.B.Ch.B., Ph.D.)



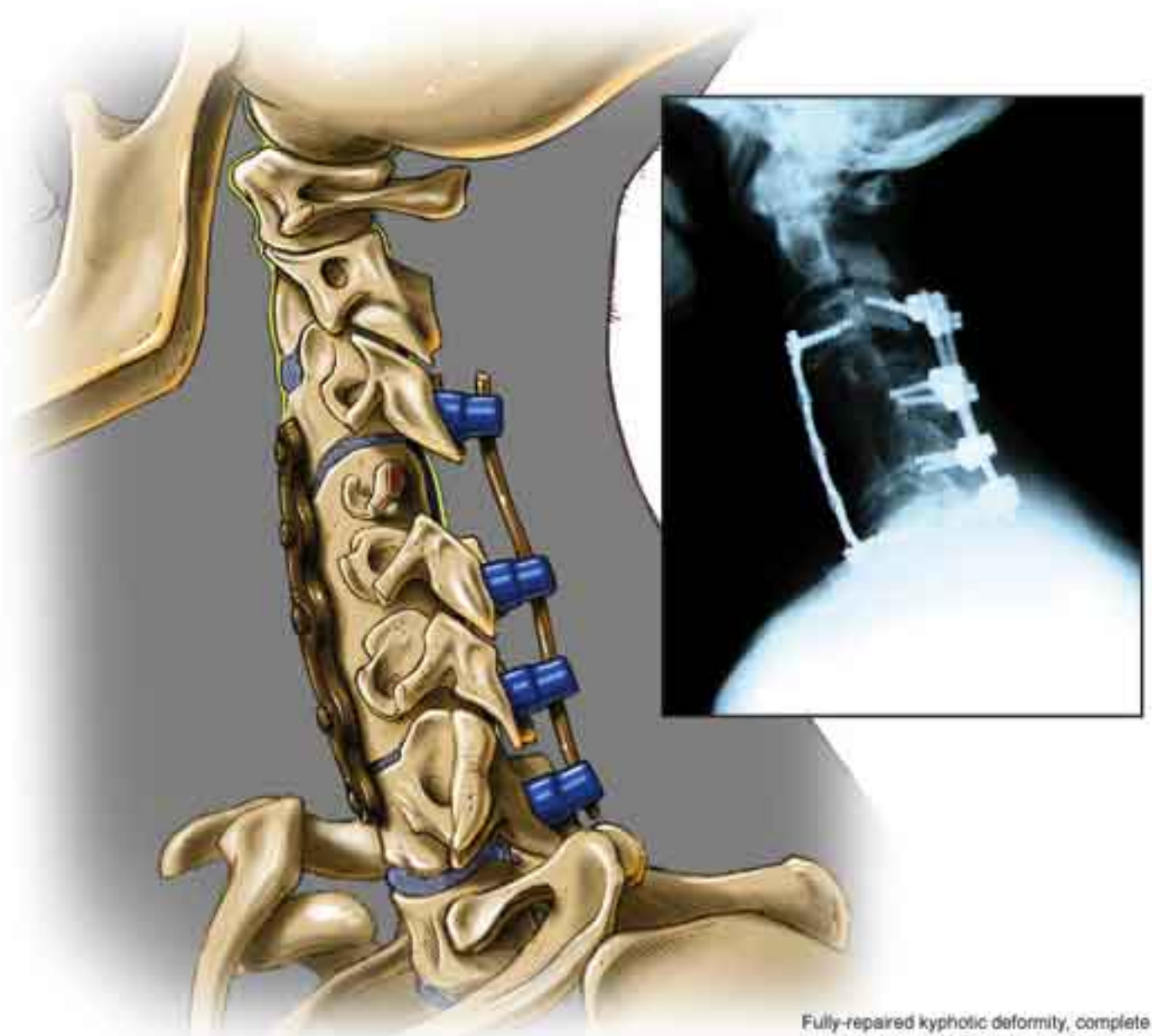
Sagittal fluoroscopic image showing corpectomy



Sagittal fluoroscopic image showing bone graft in place



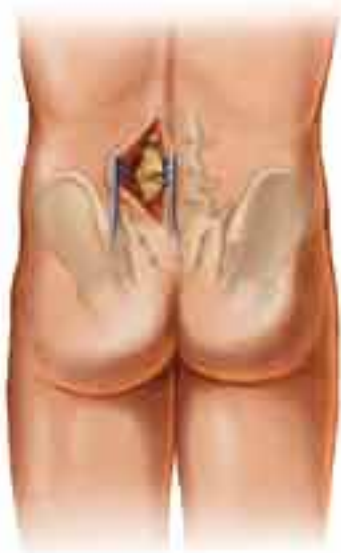Sagittal fluoroscopic image of anterior plate in place



Fully-repaired kyphotic deformity, complete with anterior plate and bilateral posterior construct, with corresponding radiograph (inset).

Clinical Spotlight: Case 2

Minimally invasive unilateral transforaminal lumbar interbody fusion (TLIF)



Surgical orientation of the TLIF procedure

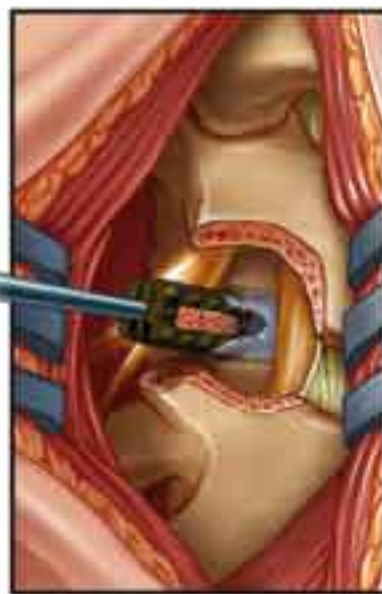Clinical Features

Lumbar fusion is a commonly performed procedure for a variety of pathological conditions, and it is frequently used in the treatment of degenerative lumbar instability that is refractory to medical management. Pedicle screws and interbody devices have been used for internal fixation to promote arthrodesis, prevent nonunion, and facilitate early mobilization. Recently, attempts have been made to reduce the morbidity associated with lumbar fusion by using a variety of minimally invasive techniques. Many minimally invasive lumbar fusion procedures require specialized retractors, implants, image guidance systems, or insertion instruments. Other minimally invasive techniques are primarily applied to an ideal patient population (thin, healthy, and with no previous surgery). The authors describe their experience with a paramedian approach for minimally invasive transforaminal lumbar interbody fusion (TLIF) with unilateral pedicle screw fixation. This procedure requires only standard implants, instruments, and retractors, with direct visualization for all aspects of the procedure. The authors describe encouraging early results in a challenging patient population in which there was a high incidence of obesity, medical comorbidities, and previous surgery at the same level. Incisions as small as 30mm have been used even in cases of reoperation. The paramedian approach for TLIF performed using unilateral lumbar pedicle screws has yielded successful outcomes in our recently published series of 47 patients, and further study of this technique may help define its role as a minimally invasive procedure for spinal fusion.

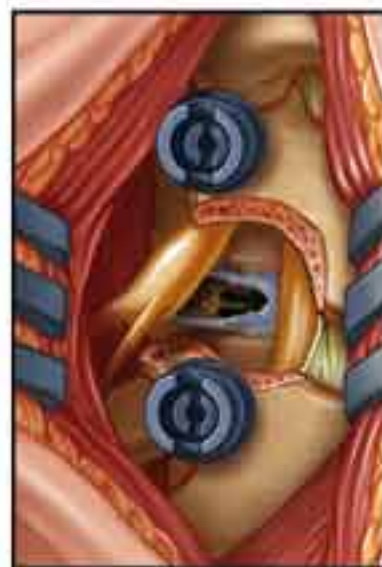(Neurosurg Focus. 2006;20(3):E5. ©2006 American Association of Neurological Surgeons)

Surgical Technique

Technical details of this procedure are described in detail in the referenced paper. An animated film segment summarizing the key points of this surgical technique is available at www.complexspinesurgery.net/movies (The illustrations pictured here refer to an identical procedure performed at the L4-5 level.)



Cage is inserted obliquely.



Pedicle screws are fastened and aligned in preparation to accommodate rod.

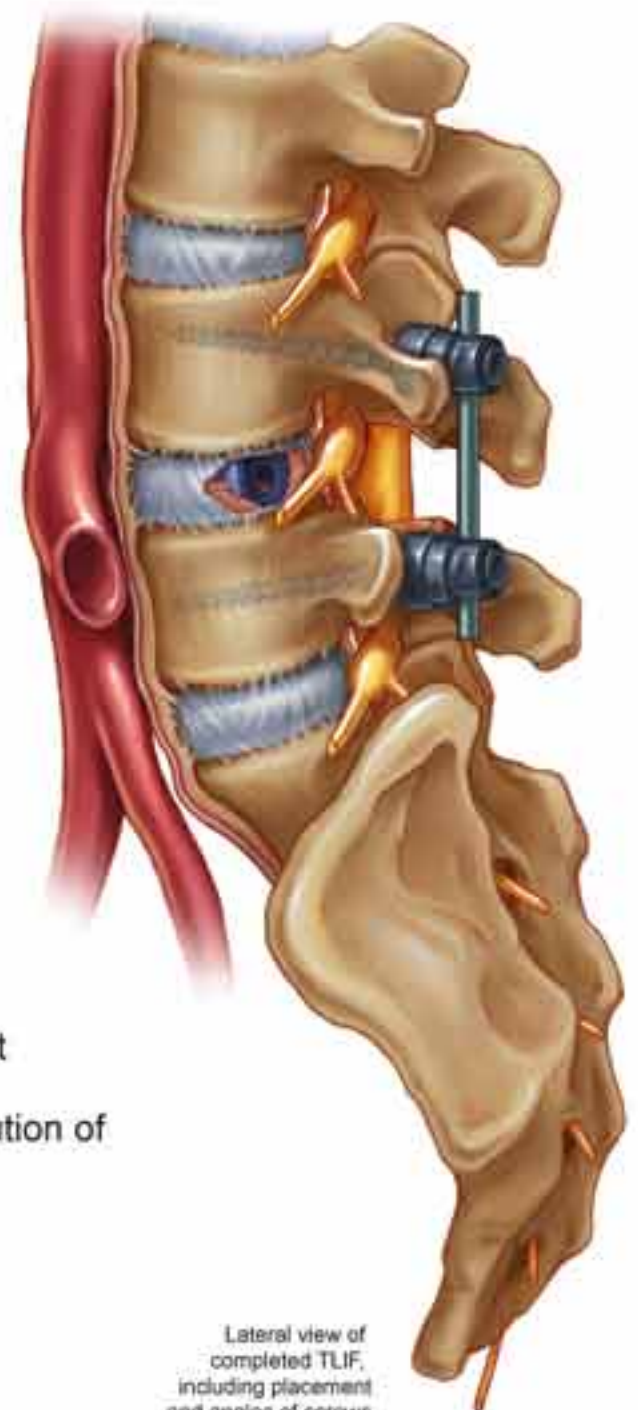
Case Presentation

The patient is a 48-year-old man with a 14-year history of low back pain and right gluteal pain. This caused him to avoid prolonged standing and interfered with both his activities at work and golf. He presented with a progressive increase in his right lower extremity radicular pain and was found to have a disc herniation at L5-S1. Fluoroscopic examination led to identification of right facet capsule incompetence resulting in intermittent compression of the right L5 nerve root associated with changes in position and activity. Although decompression of the disc may have relieved some of his radicular pain, the focal instability at the right L5-S1 facet would likely have been aggravated by any decompressive procedure and this was felt to be a significant component of his pain syndrome. This patient was not unstable to the point that bilateral fixation was felt necessary. The patient was treated with a paramedian approach for minimally invasive TLIF with unilateral pedicle screw fixation.

After surgery the patient rapidly recovered and gradually resumed activities which had not been possible for many years prior to surgery. He resumed golfing and has gone on to win a well-regarded tournament. Two years after his surgery he reported complete resolution of his back pain, even during physical activities such as golf.

He provided a video of his golf swing at two years after his fusion. This is available at www.complexspinesurgery.net/movies.

(Haroon F. Choudhri, M.D. and Walid Attia, M.B.Ch.B., Ph.D.)



Lateral view of completed TLIF, including placement and angles of screws

Presentations and Publications (July-December 2006)

Presentations

Witcher MR, Kirov SA, Harris KM: Astroglial processes support larger synapses but do not limit their potential for synaptic crosstalk. *Glia in Health & Disease*. Cold Spring Harbor Laboratory. July 2006 (Poster)

Nagendran T, Dhandapani KM, Alleyne CH: Hemin induces the gene expression of inflammatory mediators in murine cortical astrocytes. Congress of Neurological Surgeons Meeting. Chicago, IL, October 2006 (Poster)

Rahimi S, Vender JR, Macomson SD, Smith JR, Alleyne CH: Post-operative pain management following craniotomy: Evaluation and cost analysis. Congress of Neurological Surgeons Meeting. Chicago, IL, October 2006 (Poster)

Kirov SA, Boehnke SE, Andrew RD: Real-time volume responses of astrocytes to osmotic and ischemic stress in cortical brain slices. The 36th SFN Annual Meeting. Atlanta, GA, October 2006 (Poster)

Douglas HA, Yang G, Andrew RD, Kirov SA: Two-photon microscopical study of pyramidal neurons protected from ischemic stress by dibucaine. The 36th SFN Annual Meeting. Atlanta, GA, October 2006 (Poster)

Andrew R, Kirov SA: Imaging brain trauma using 2-photon microscopy in real time: Stroke studies reveal its potential. The 3rd Australian Health & Medical Research Congress (AH&MRC). Melbourne, Australia, November 2006 (Poster)

Andrew RD, Kirov SA: Real-time imaging of neurons and glia in cerebral cortex during ischemia and osmotic stress. The 3rd Australian Health & Medical Research Congress (AH&MRC). Melbourne, Australia, November 2006 (Poster)

Pillai A, Dhandapani KM, Buckley PF, Mahadik SP: Do neurotrophins have therapeutic potential in Schizophrenia? Erythropoietin prevents haloperidol toxicity through increased expression of BDNF. International Congress on Schizophrenia Research. 2006

Mahadik SP, Pillai A, Dhandapani KM: Vascular endothelial growth factor mediates the neuroprotective effects of antipsychotic treatment in cortical neuronal culture. International Congress on Schizophrenia Research. 2006

Publications

Fountas KN, Lee GP, Smith JR: Outcome of patients undergoing gamma knife stereotactic radiosurgery for medically refractory trigeminal neuralgia: Medical College of Georgia's Experience. *Stereotact Funct Neurosurg* 84: 88-96, 2006

Sorra KE, Mishra A, Kirov SA, Harris KM: Dense core vesicles resemble active-zone transport vesicles and are diminished following synaptogenesis in mature hippocampal slices. *Neuroscience* 141:2097-2106, 2006

Bourne JN, Kirov SA, Sorra KE, Harris KM (2006) Warmer preparation of hippocampal slices prevents synapse proliferation that might obscure LTP-related structural plasticity. *Neuropharm* Aug 6, 2006 [Epub. ahead of print].

Witcher MR, Kirov SA, Harris KM (2007) Plasticity of perisynaptic astroglia during synaptogenesis in the mature rat hippocampus. *Glia*. 55(1): 13-23, 2007 [Epub. ahead of print; (2006) Sep 25].

Publications (continued...)

Alleyne CH, Barrow DL: ICA Aneurysms: Supraclinoid, Eds: Fessler RG and Sekhar LN: Atlas of Neurosurgical Techniques. New York, Thieme Medical Publishers, Inc., 2006, pp 108-116

Rahimi SY, Vender JR, Macomson SD, French A, Smith JR, Alleyne CH: Postoperative pain management after craniotomy: Evaluation and cost analysis. *Neurosurgery* 59:852-857, 2006

Vender JR, Hughes BD, Figueroa R, Jensen MA: Temporomandibular joint cyst presenting as trigeminal neuropathy and middle fossa mass: Case report. *Neurosurgery* 59:938, 2006

Rahimi SY, Hamilton WB, Alleyne CH, Choudhri HF, Lee MR: Patient and family-centered care initiative: Implementation at the Medical College of Georgia. *AANS Bulletin* 15:12-15, 2006

Hughes BD, Vender JR: Delayed lead pulmonary emboli after a gunshot wound to the head. Case report. *J Neurosurg* 105:233-4, 2006

Vender JR, Hughes M, Hughes BD, Hester S, Holsenback S, Rosson B: Intrathecal baclofen therapy and multiple sclerosis: outcomes and patient satisfaction. *Neurosurgical Focus* 21(2):E6, 2006.

Mahesh VB, Dhandapani KM, Brann DW: Role of astrocytes in reproduction and neuroprotection. *Mol Cell Endocrinology* 246: 1-9, 2006

Dhandapani KM, Brann DW: Role of astrocytes in estrogen-mediated neuroprotection. *Exp Gerontol* 42: 70-75, 2006

Hamilton WB, Teaching the Business of Medicine. *AANS Bulletin* 15: 24, 2006

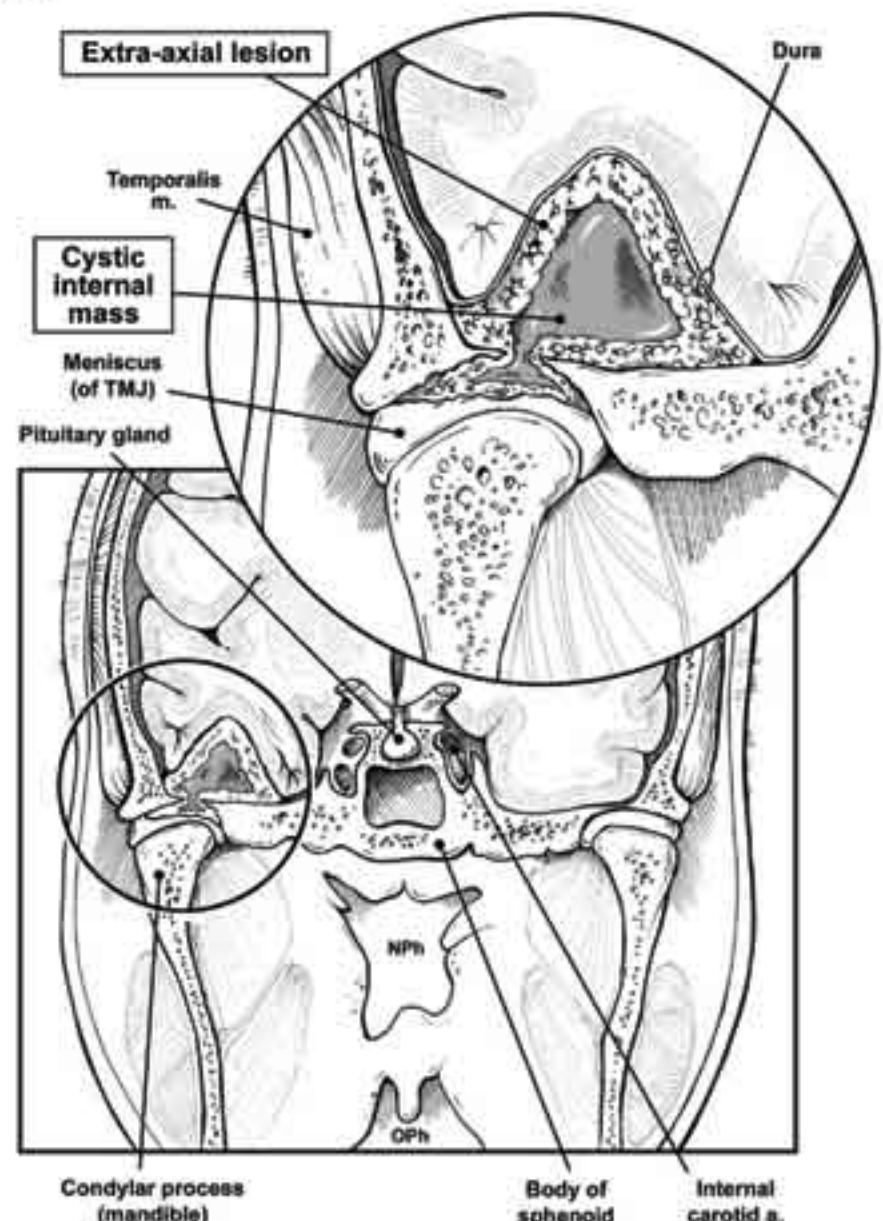


Illustration for "Temporomandibular joint cyst presenting as trigeminal neuropathy and middle fossa mass"



Department of Neurosurgery
 Medical College of Georgia
 1120 15th Street
 Augusta, GA 30912
 706. 721. 3071

Neuroscience Outlook

To learn more about the MCG Department of Neurosurgery, please visit:
www.mcg.edu/som/neurosurgery

Conference Schedule (January 2007 - June 2007)

All grand rounds and conferences take place on Friday in the 3 West amphitheater.

Jan 12	9:00 - 10:00 10:00 - 11:00 11:00 - 12:00 12:00 - 1:00	Neuro 101: Dr. Hamid Shah "Brachial Plexus Lesions" Spine Conference Case Conference Brain Tumor Board	Mar 02	9:00 - 10:00 10:00 - 11:00 11:00 - 12:00 12:00 - 1:00	Journal Club Spine Conference Case Conference Brain Tumor Board	May 04	9:00 - 10:00 10:00 - 11:00 11:00 - 12:00 12:00 - 1:00	Journal Club Spine Conference Case Conference Brain Tumor Board
Jan 19	9:00 - 10:00 10:00 - 11:00 11:00 - 12:00 12:00 - 1:00	Anatomy Spine Conference Radiology Review Brain Tumor Board	Mar 09	9:00 - 10:00 10:00 - 11:00 11:00 - 12:00 12:00 - 1:00	Neuro 101: Dr. Ahmed Shakir "TBA" Spine Conference Case Conference Brain Tumor Board	May 11	9:00 - 10:00 10:00 - 11:00 11:00 - 12:00 12:00 - 1:00	Anatomy Spine Conference Case Conference Brain Tumor Board
Jan 26	9:00 - 10:00 10:00 - 11:00 11:00 - 12:00 12:00 - 1:00	Neuro 101: Dr. John Vender "Neurocutaneous Syndromes" Spine Conference M&M Brain Tumor Board	Mar 16	9:00 - 10:00 10:00 - 11:00 11:00 - 12:00 12:00 - 1:00	Anatomy Spine Conference Radiology Review Brain Tumor Board	May 18	9:00 - 10:00 10:00 - 11:00 11:00 - 12:00 12:00 - 1:00	Core Curriculum Spine Conference Radiology Review Brain Tumor Board
Feb 02	9:00 - 10:00 10:00 - 11:00 11:00 - 12:00 12:00 - 1:00	Journal Club Spine Conference Case Conference Brain Tumor Board	Mar 23	9:00 - 10:00 10:00 - 11:00 11:00 - 12:00 12:00 - 1:00	Neuro 101: Dr. Scott Rahimi "Vascular Malformations" Spine Conference M&M Grand Rounds: Dr. Guy McCain	May 25	9:00 - 10:00 10:00 - 11:00 11:00 - 12:00 12:00 - 1:00	Core Curriculum Spine Conference M&M Brain Tumor Board
Feb 09	9:00 - 10:00 10:00 - 11:00 11:00 - 12:00 12:00 - 1:00	Neuro 101: Dr. Haroon Choudhri "Degenerative Disc Disease" Spine Conference Case Conference Brain Tumor Board	Mar 30	NO CONFERENCE		Jun 01	9:00 - 10:00 10:00 - 11:00 11:00 - 12:00 12:00 - 1:00	Journal Club Spine Conference Case Conference Brain Tumor Board
Feb 16	9:00 - 10:00 10:00 - 11:00 11:00 - 12:00 12:00 - 1:00	Anatomy Spine Conference Radiology Review Grand Rounds: Mark Schornak Barrow Neurological Institute "The Development of Multimedia for Teaching Skullbase Approaches and Neuroanatomy at BNI"	Apr 06	NO CONFERENCE / MASTERS WEEK		Jun 08	9:00 - 10:00 10:00 - 11:00 11:00 - 12:00 12:00 - 1:00	Anatomy Spine Conference Case Conference Brain Tumor Board
Feb 23	9:00 - 10:00 10:00 - 11:00 11:00 - 12:00 12:00 - 1:00	Neuro 101: Dr. Jonathan Tuttle "Osodontoideum Congenital Spine Disease" Spine Conference M&M Brain Tumor Board	Apr 13	9:00 - 10:00 10:00 - 11:00 11:00 - 12:00 12:00 - 1:00	Neuro 101: Dr. Haroon Choudhri "Thoracolumbar Spine Trauma" Spine Conference Case Conference Brain Tumor Board	Jun 15	9:00 - 10:00 10:00 - 11:00 11:00 - 12:00 12:00 - 1:00	Core Curriculum Spine Conference Radiology Review Brain Tumor Board
			Apr 20	9:00 - 10:00 10:00 - 11:00 11:00 - 12:00 12:00 - 1:00	Anatomy Spine Conference M&M Brain Tumor Board	Jun 22	9:00 - 10:00 10:00 - 11:00 11:00 - 12:00 12:00 - 1:00	Core Curriculum Spine Conference M&M Brain Tumor Board
			Apr 27	9:00 - 10:00 10:00 - 11:00 11:00 - 12:00 12:00 - 1:00	Neuro 101: Dr. David Floyd "Clinical Localization in Disc Disease" Spine Conference M&M Brain Tumor Board	Jun 29	NO CONFERENCE	

Upcoming Meetings (January - June 2007)

AANS/CNS Cerebrovascular Section and American Society of Interventional and Therapeutic Neuroradiology (International Stroke Conference)
 2/7-9, San Francisco, CA

AANS/CNS Section on Disorders of the Spine & Peripheral Nerves
 3/7-10, Phoenix, AZ

Southern Neurosurgical Society
 3/14-17, Sea Island, GA

American Association of Neurological Surgeons
 4/14-19, Washington, D.C.

Society of Neurological Surgeons
 5/6-8, San Francisco, CA

Georgia Neurosurgical Society
 5/24-27, Sea Island, GA

Credits

Editor-in-Chief:
Cargill H. Alleyne, Jr., M.D.

Illustration, design and layout:
Michael A. Jensen, M.S., Andy Rekito, M.S.

Contributors:
Mark R. Lee, M.D., Ph.D., Haroon F. Choudhri, M.D., Walid Attia, M.B.Ch.B., Ph.D., Sergei A. Kirov, Ph.D., Alfredo D. Voloschin, M.D., Cargill H. Alleyne, Jr., M.D.

MCG
 Neuroscience Center

For information or inquiries:

please call
(706) 721-3071

or e-mail Bill Hamilton
whamilton@mcg.edu

www.mcg.edu/som/neurosurgery