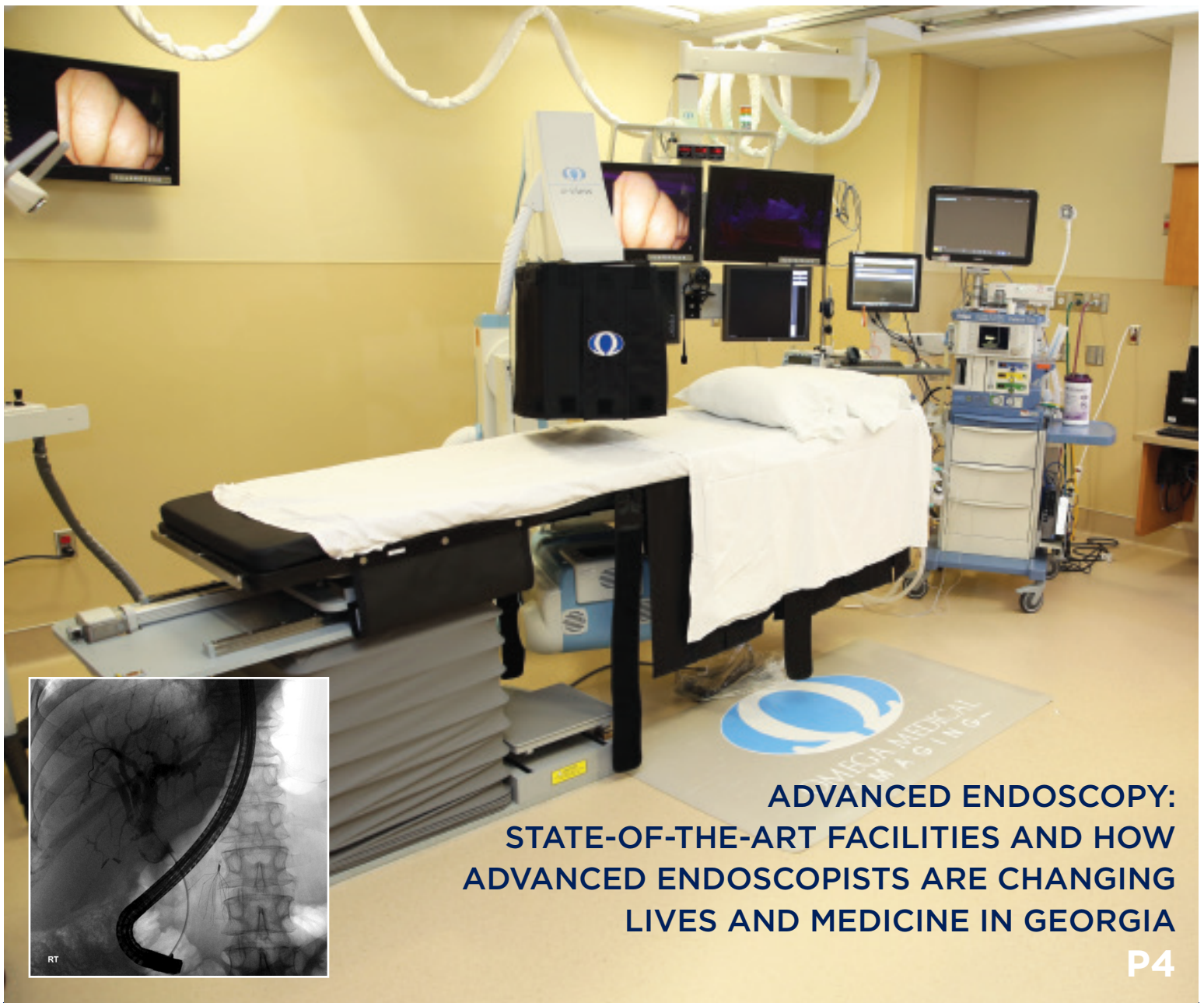




# DIGESTIVE MATTERS



**ADVANCED ENDOSCOPY:  
STATE-OF-THE-ART FACILITIES AND HOW  
ADVANCED ENDOSCOPISTS ARE CHANGING  
LIVES AND MEDICINE IN GEORGIA**

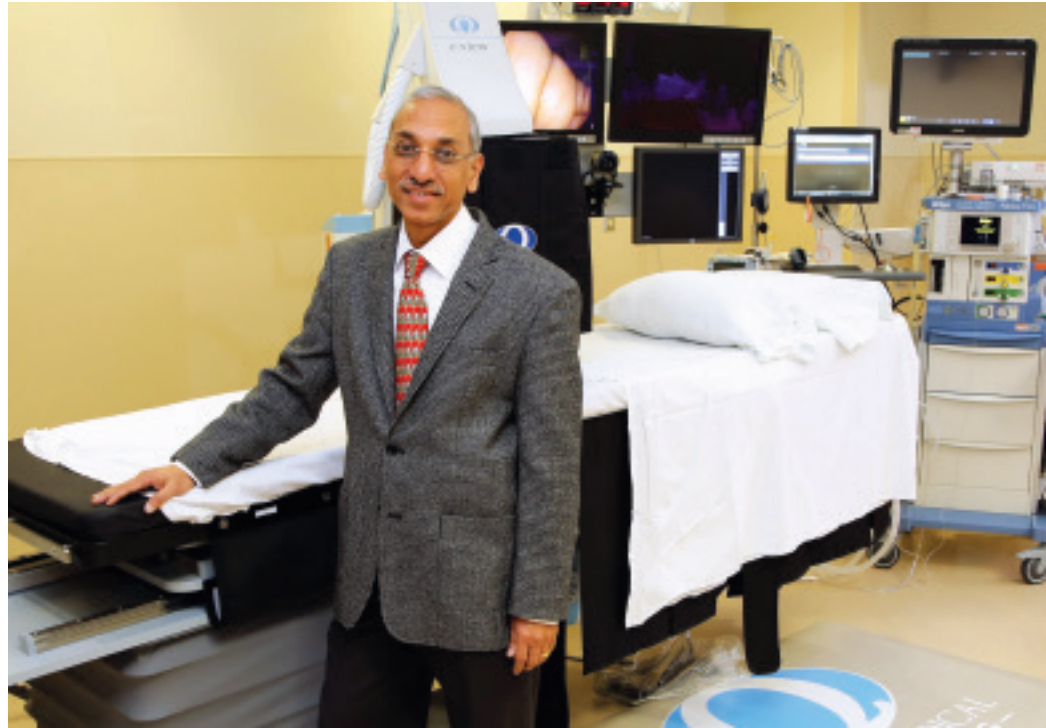**P4**

# MESSAGE FROM THE DIRECTOR

**W**elcome to the second volume of Digestive Matters. It is amazing how time flies and six months have elapsed since the previous edition. Although we have made many strides in several disciplines within digestive health and have cured many patients with a variety of problems and yes, would love to share them all space constraints dictate otherwise.

You will learn first-hand how our experts in the Digestive Health Center, notably Drs. John Affronti, Subbaramiah Sridhar and Sumanth Daram are using their unique skills and talents to diagnose and treat complex gastrointestinal problems that is only possible at the DHC.

You will read about Frank Thomas who was referred with an unsuspected growth in his esophagus (food pipe) and how endoscopic ultrasound and a new minimally invasive technique of video-assisted thoracoscopic surgery (VATS) performed by Dr. Carsten Schroeder, a nationally renowned thoracic surgeon enabled his full recovery.



---

**“A positive attitude is contagious, but don’t wait to catch it from others, be a carrier.”**

**Anonymous**

---

And then there is Allen Rowe who presented with flu-like symptoms and jaundice and who was initially diagnosed with a stricture (blockage) of bile ducts (pipes that connect the liver with the intestine), possibly due to a cancer. Dr. Daram used the novel revolutionary technique of Spyglass, an instrument half the thickness of a pencil, to facilitate a surprise diagnosis.

The Digestive Health Center has six regular endoscopy rooms and three advanced endoscopy and fluoroscopy suites with state-of-the-art facilities for both diagnosis and management of pancreatico-biliary disorders as well as complex cancers in the abdomen and chest. We use minimally invasive technology without major surgery for diagnosis and treatment of gallstones, strictures, pancreatic cysts, endoscopic removal of large polyps, radiofrequency ablation of Barrett’s dysplasia, endoscopic mucosal resection and celiac plexus block for chronic abdominal pain or for stenting of

many digestive organs.

Also in this issue we are introducing a new Section “DHC Highlights” that will provide a GI quiz for diagnosis, a practical tid-bit for diet and nutrition, a top-line summary of the latest advances in GI/hepatology and upcoming DHC news.

Finally, we wish to share some of the key features and outstanding achievements of our DHC team which are summarized in our annual report.

The DHC not only provides world-class health care, but its research team is toiling hard to develop the next best test to improve diagnosis of common GI problems and to pioneer new treatments where there is none. We implore you to please join us in our campaign to promote colon cancer awareness through early diagnosis and treatment, cure hepatitis C, prevent and treat obesity, develop cutting-edge therapies for ulcerative colitis and Crohn’s disease, and quite importantly to diagnose and treat gastroparesis, fecal incontinence, IBS and constipation. Toward

this important mission, we are launching a fundraising campaign to support our research infrastructure and research programs. We hope you will consider supporting our endeavors, so that we can provide the best care for our patients and keep our department on the cutting edge. To learn more about how you can make a gift, please contact David Cantrell at 706-721-1817 or [dcantrell@gru.edu](mailto:dcantrell@gru.edu).

I trust you will enjoy reading this issue, and please contact me with suggestions or advice.

Respectfully,

**Satish SC Rao, MD, PhD, FRCP**  
Professor of Medicine  
Chief, Gastroenterology/Hepatology  
Director, Georgia Regents  
Digestive Health Center

# IN THIS ISSUE

---

WINTER 2015

**I**n this issue, you will discover how the new generation of cutting-edge technology has revolutionized our approach and management of complex gastrointestinal problems at the Digestive Health Center. We will focus on Advanced Endoscopy and Gastrointestinal Services (AEGIS), in particular, endoscopic retrograde cholangio pancreatography (ERCP), endoscopic ultrasound (EUS), Spyglass and other technologies.

ADVANCED ENDOSCOPY \_\_\_\_\_ 4

PATIENT TESTIMONIALS \_\_\_\_\_ 6

DHC UPDATE & HIGHLIGHTS \_\_\_\_\_ 8

MEET OUR TEAM \_\_\_\_\_ 10

GRATEFUL PATIENT GIVES BACK \_\_\_\_\_ 12

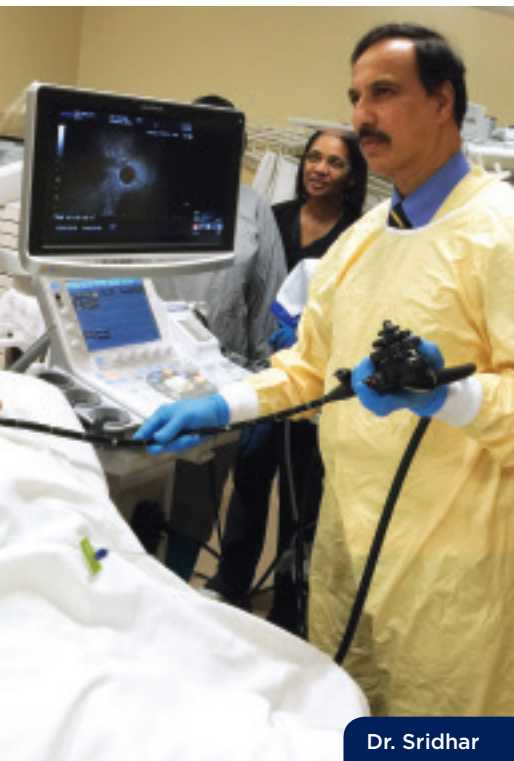## ABOUT THE COVER

Advanced Endoscopy suite with state-of-the-art equipment at DHC. Insert shows an ERCP image. Read more on page 4.

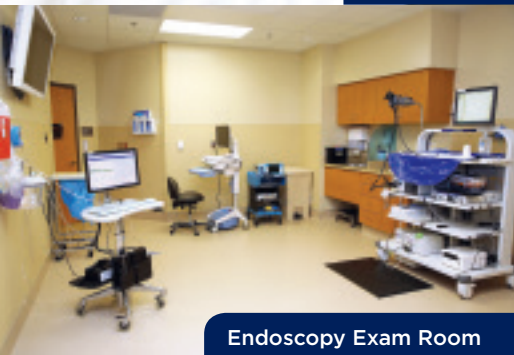


# ADVANCED ENDOSCOPY: MINIMALLY INVASIVE ALTERNATIVES FOR GASTROINTESTINAL PROBLEMS

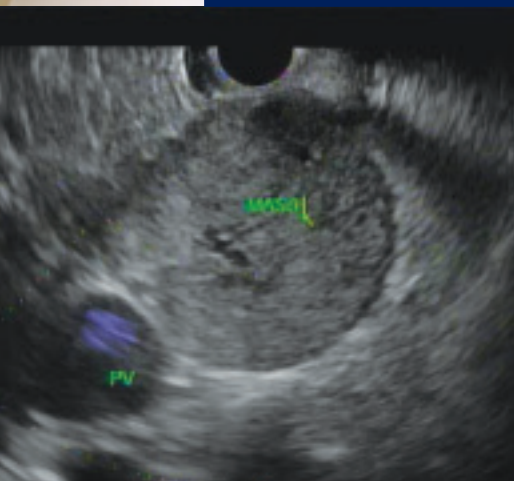If you're suffering from a digestive health disorder, consider a gentler option for treatment. The Advanced Endoscopy & Gastrointestinal Service (AEGIS) at the Georgia Regents Digestive Health Center offers a wide range of highly advanced, minimally invasive alternatives to standard invasive diagnostic and surgical procedures. Our multidisciplinary advanced endoscopy team has more than 50 years' experience in diagnosing and caring for:



Dr. Sridhar



Endoscopy Exam Room



Ultrasound image

## General disorders affecting the esophagus, stomach and duodenum, and colon and rectum

- Management of large complicated polyps, or abnormal tissue growth
- Diagnosis and treatment of fistula, abnormal connection between vessels or intestines due to infection or inflammation
- Diagnosis of cancer, or lymphadenopathy, swollen or enlarged lymph nodes outside the gut wall either in the chest or inside the abdomen

## Specific esophageal disorders

- Barrett's esophagus, a complication of gastroesophageal reflux disease (GERD) that can cause dysplasia, or abnormal cell changes, and increase risk of cancer
- Perforation, a hole in the esophagus caused by injury
- Submucosal mass, a tumor in the submucosa layer of the lining of the esophagus or digestive tract

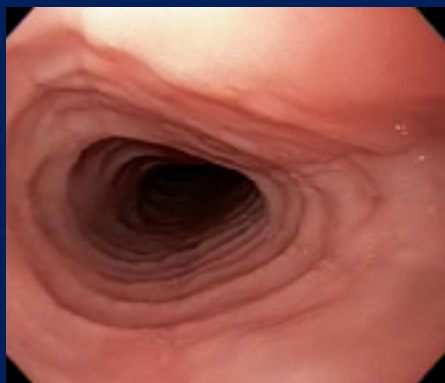## Pancreas and bile duct disorders

- Stones in the bile duct (choledocholithiasis) or gallbladder (cholelithiasis)
- Infection of the bile duct (cholangitis)
- Cancer of the bile duct or gallbladder
- Inflammation of the pancreas (acute or chronic pancreatitis)
- Cyst in the pancreas or bile duct (choledochocele)
- Mass in the pancreas or in the ampulla of Vater, an area where the bile duct and pancreatic duct join
- Bile duct muscle dysfunction (Sphincter of Oddi dysfunction), causing abdominal pain

## Take the Quiz

Seigfried Yu, MD

An 18 year-old was seen in the ER with food impaction after eating steak. He describes mid-chest discomfort and pooling salivary secretions. He has a history of severe allergic rhinosinusitis. The meat bolus was disimpacted successfully with an endoscopy which also revealed the following findings:

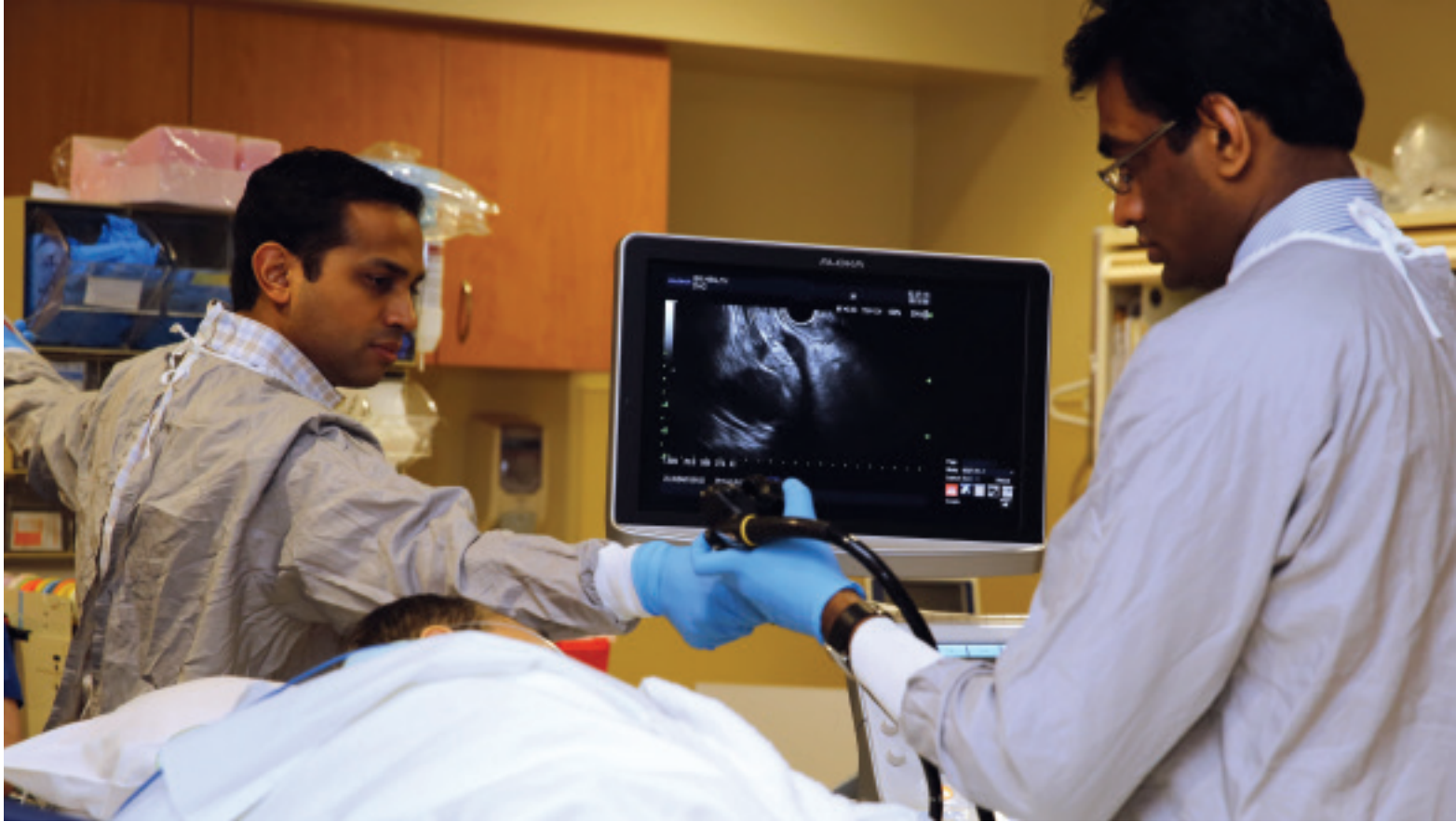

Which of the statements below is true about the further management of this patient?

- Treatment with antihistamines improves this dysphagia.
- Botulinum toxin injection is considered first-line therapy.
- If the patient does not respond to PPI therapy, an Anti-TNF biologic agent would be indicated.
- A course of PPI bid with singulair is usually first line of treatment.
- Esophageal dilation is contraindicated.

*D. The picture depicts distinct rings, consistent with eosinophilic esophagitis (EoE). Esophageal dilation is safe in most patients with EoE to address dominant strictures.*

**ANSWER:**



### Technologically Advanced Care

Sharper images in real time. Greater detail. 3-D imaging. GRHealth's ongoing partnership with Philips, a worldwide leader in health care electronics, means that we have the most advanced technology available today at our fingertips, allowing us to deliver better care and the latest minimally invasive treatments to you and your family.

Our procedures include:

- Bariatric endoscopy, endoscopic management of complications after weight-loss surgery
- Complex polypectomy, removal of polyps or small growths found during a colonoscopy
- Deep/device-assisted enteroscopy or small bowel endoscopy, which looks deep inside the small intestine to diagnose digestive disorders
- Endoscopic ablation therapy (HALO), a nonsurgical procedure for Barrett's esophagus that uses a special catheter and heat to remove diseased or precancerous tissue in the esophagus
- Endoscopic celiac plexus block/neurolysis. These nerve block injections help reduce often intense, hard-to-treat pain in patients with pancreatic cancer or chronic pancreatitis

- Endoscopic mucosal resection (EMR), nonsurgical removal of cancerous or other abnormal tissues from the digestive tract for patients with Barrett's esophagus
- Endoscopic therapy for Barrett's esophagus, including EMR, endoscopic mucosectomy (removal of the mucosal layer), and radiofrequency ablation
- Endoscopic ultrasound (EUS). This procedure allows physicians to examine the lining and walls of the upper and lower gastrointestinal tract using a tube with an ultrasound component. EUS is commonly used to evaluate and drain cysts, stage and manage cancer, and evaluate and perform fine needle aspiration of masses and/or lymph nodes
- Endoscopic retrograde cholangiopancreatography (ERCP). This procedure allows physicians to examine pancreatic and bile ducts using contrast material and fluoroscopy (X-ray). ERCP is commonly used for stent placement, stone removal and fracture (lithotripsy), stricture dilation (opening narrowed areas), and tumor sampling and management
- Enteral stent placement. Stents, hollow mesh tubes, may be placed in the digestive tract to correct narrowed areas caused by disease or illness
- Enteral tube/feeding tube placement and venting gastrostomy. During this procedure, an endoscope is inserted through the mouth and into the stomach for the placement of a feeding tube. ●

## MEET OUR ADVANCED ENDOSCOPY TEAM

### Dr. John Affronti,

Advanced Endoscopy, Biliary/Pancreas and Director, AEGIS

### Dr. Sumanth Daram,

Advanced Endoscopy, Biliary/Pancreas

### Dr. Subbaramiah Sridhar,

Advanced Endoscopy, Biliary/Pancreas

### Amanda Lee ARNP,

Nurse Practitioner



# PATIENT TESTIMONIALS

*Allen Rowe, Spyglass Direct Visualization System*



Allen Rowe

**F**or Allen Rowe, 81, his case began with something simple: He thought he had the flu. But his doctor thought otherwise: “He said, ‘I think you have gallstones.’”

Tests confirmed not only stones but a stricture in the bile duct that required stents—and possible gallbladder removal. Then the word “cancer” was mentioned, and Rowe was referred to Dr. Sumanth Daram and GRHealth Digestive Health Center, which offers the area’s only endoscopic ultrasound, for further testing.

After part of his gallbladder was removed, Rowe continued to be followed by Dr. Daram, an interventional gastroenterologist and specialist in biliary/pancreas, to manage his gallbladder and assess for possible cancer. He received endoscopic ultrasounds, tissue biopsies and stent replacements every two to four months over the course of three years.

---

**“When I first met Dr. Daram and the rest of the staff at the GRHealth Digestive Health Center, I felt immediately comfortable. I was confident in the people I talked to, that they knew what they were doing and I was going to get taken care of. And he’s been watching me like a hawk ever since!”**

---

“After an endoscopy visit, it takes about a week to get over it,” said Rowe, who also suffers from heart arrhythmia. “It drains the heck out of me.”

But then, a new technology: SpyGlass Direct Visualization System. Ideal for older patients or those with underlying health issues, the system helps reduce the need for endoscopic ultrasound by offering a clear and magnified view into the bile duct, viewable to the naked eye.

Rowe’s SpyGlass procedure found that his bile duct was completely benign. As a result, he now will see Dr. Daram and the Digestive Health Center team in six months. “When I first met Dr. Daram and the rest of the staff at the GRHealth Digestive Health Center, I felt immediately comfortable. I was confident in the people I talked to, that they knew what they were doing and I was going to get taken care of,” said Rowe. “And he’s been watching me like a hawk ever since!” ●

## Frank Thomas, Endoscopic Ultrasound

**W**hen Frank Thomas, 66, first saw an image of the tumor pressing on his esophagus, he was shocked at how large it was. Especially since he had felt no symptoms.

Thomas was lucky. A CT scan and GI series related to his heart arrhythmia uncovered the mass—and his cardiologist at GRHealth immediately referred him to Dr. John Affronti, Director of Advanced Endoscopy and Gastrointestinal Services at GRHealth Digestive Health Center.

Affronti immediately used endoscopic ultrasound to pinpoint the depth of involvement, location and stage of the tumor, and Thomas was even luckier: The mass had not yet extended to the muscle layer and was contained. As a result, the tumor board advised that he undergo VATS surgery, without the need for further chemotherapy or radiation.

In this region, VATS or video-assisted thoracoscopic surgery is only available at GRHealth Digestive Health Center (other facilities offering the procedure are two-plus hours away). Offered by Dr. Carsten Schroeder, the advanced technique relies on a tiny camera and tools inserted through several small incisions through the chest. The minimally invasive procedure results in faster recovery, less pain, fewer complications and the same oncologic results as open surgery.

Despite a few complications, Thomas was eating ice cream in his hospital bed a week after surgery. “I felt great,” he remembered. “They said they got it all and that I wasn’t going to have to go through the radiation treatments and chemotherapy, and all that made it 10 times better.”

Today, Thomas is free and clear of cancer and has no need to visit the GRHealth Digestive Health Center (other than scheduled colonoscopies, one of which he completed earlier this year). He’s back to working as a radiological control inspector at Savannah River Site and just enjoying his life.

“This was my first real stay in a hospital and my first-ever surgery,” said Thomas. “I expected it to be really, really bad, but it wasn’t. It was good, and those folks—they really take care of you...I’m doing well and I’m back at work—and I still eat steak!” ●

---

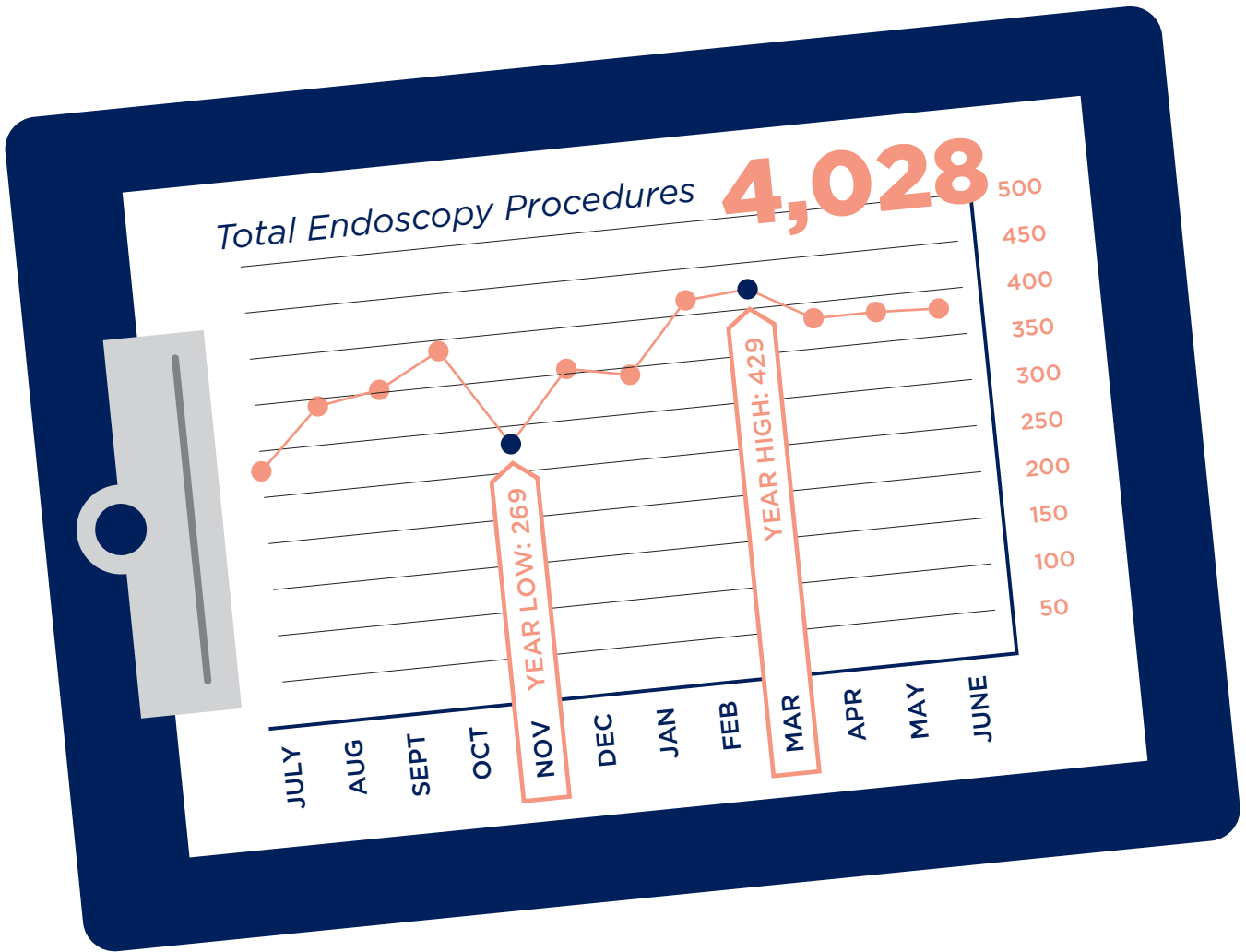
**“This was my first real stay in a hospital and my first-ever surgery...I expected it to be really, really bad, but it wasn’t. It was good, and those folks—they really take care of you...I’m doing well and I’m back at work—and I still eat steak!”**

---



Frank Thomas

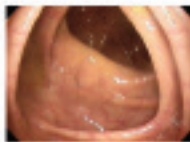# 2015 ANNUAL REPORT



## FUSE SCOPE

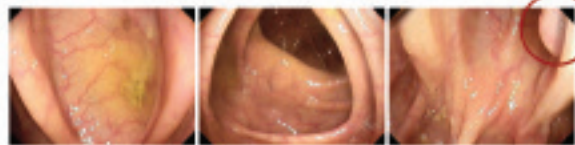**DHC offers the latest in 330 view scope - one of the first in Georgia.**

A new generation of colonoscopes has been developed, allowing for 330-degree forward view. These Fuse® colonoscopes have been shown to increase the rate of detection of colon polyps by 69 percent and are currently being used in daily practice at the DHC.



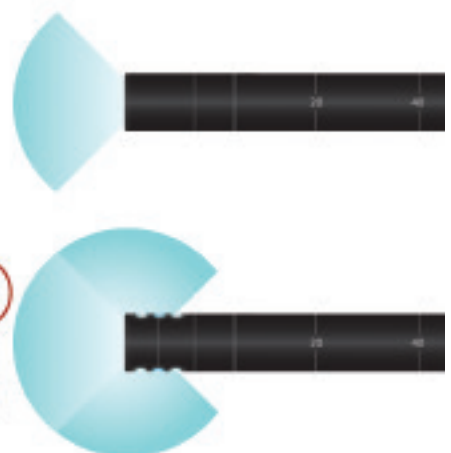
Traditional Colonoscope

**Limited 170° Field of View**



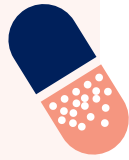Fuse® Colonoscope

**Panoramic 330° Field of View**





# NEW DRUGS

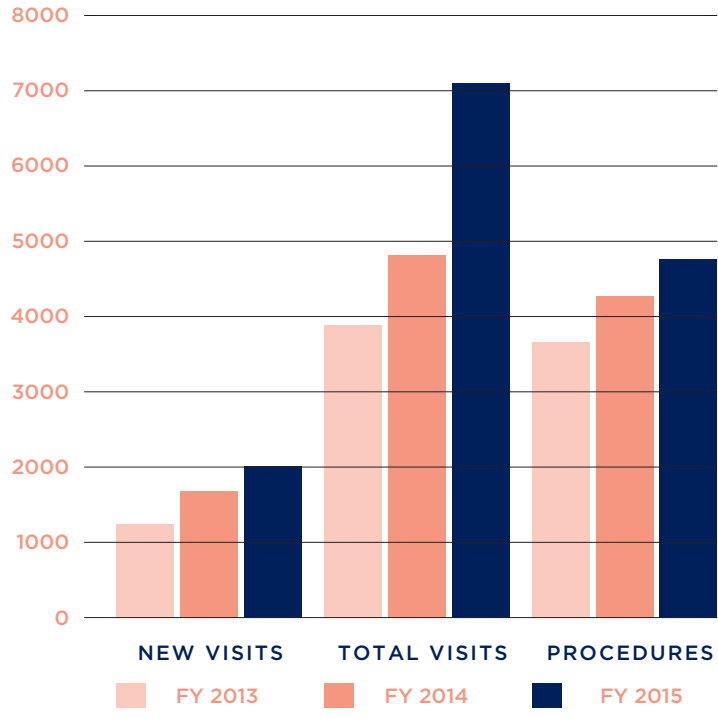


Drug development for hepatitis C has revolutionized our ability to cure and eradicate this disease. The combination of well-tolerated medications in a once daily pill, Harvoni®, achieves cure rates in greater than 90 percent of patients regardless of prior treatment. Unfortunately, without an aggressive specialty pharmacy, such as one found at DHC, access to this medication remains limited in the community.

**New Drug: HARVONI®**

**Indication: Hepatitis C**

## DHC CLINIC VOLUMES TRENDING POSITIVE

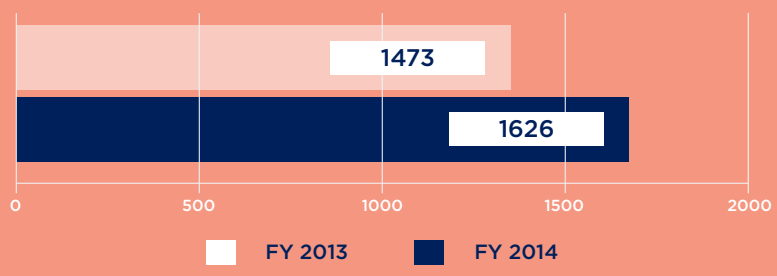


**2,004**  
NEW VISITS

**7,085**  
TOTAL VISITS

**4,886**  
PROCEDURES

### MOTILITY PROCEDURES



**New Drug: ENTVYIO®**



**Indication: IBD**

Finally, the new medication, Entvyio®, available to our DHC patients, offers IBD patients not responsive to prior anti-TNF therapy a promising treatment option with a completely novel mechanism of action.

**Treatment: NALOXEGOL**




Naloxegol is a new treatment that allows patients to continue opioid pain medication while reversing opioid induced constipation and other undesirable side effects.

# MEET OUR TEAM

If you have a digestive health disorder, big or small, we can help. As part of the region's only comprehensive digestive health center, our physicians are specially trained and experienced in virtually every subspecialty of gastroenterology — from advanced endoscopy to hepatology to IBD and neurogastroenterology and motility.

Our center director, Satish Rao, MD, is an international leader in digestive health disorders. He is past president of the American Neurogastroenterology and Motility Society, a recipient of the three highest honors from the American Gastroenterological Association, and a federally funded investigator.



**Satish Rao, MD**  
Director, Digestive Health Center & Professor of Medicine & Program Director

**Specialties:** Neurogastroenterology & GI Motility, Nutrition, Gastroenterology  
**Research:** Brain-Gut Interactions, Constipation, Biofeedback Therapy, Fecal Incontinence, IBS, Gastroparesis, Dietary Fructose Intolerance, 3-D Anorectal Evaluation, Magnetic Therapy, Novel Diagnostic Tools for GI Motility



**John Affronti, MD**  
Director of Advanced Endoscopy, Pancreas & Bile Duct Group & Professor of Medicine

**Specialties:** Advanced Endoscopy, Gastroenterology, Digestive Health  
**Research:** Pancreas and Bile Duct Disorders, Endoscopic Ultrasound (EUS), Endoscopic Retrograde Cholangiopancreatography (ERCP) Advanced Endoscopy Technology, Endoscopy Training, Quality and Clinical Outcome Metrics



**Thomas Kiernan, MD**  
Emeritus Professor Hepatology Gastroenterology

**Specialties:** Hepatology  
**Research:** Hepatitis C



**Sumanth Reddy Daram, MD**  
Interventional Gastroenterologist, Advanced Endoscopy, Associate Professor of Medicine

**Specialties:** ERCP, Endoscopic Ultrasound, Gastroenterology, Digestive Health  
**Research:** Clinical Outcomes, Therapeutic EUS, Endoscopic Videos in Education, EUS Tissue Sampling



**Sandeep Khurana, MD**  
Director, Hepatology and Associate Professor of Medicine

**Specialties:** Hepatology, Gastroenterology, Digestive Health  
**Research:** Cholinergic Mechanisms of Liver Injury, Portal Hypertension, Hepatitis C Non-Alcoholic Fatty Liver Disease




**Subbaramiah Sridhar, MD**  
Professor of Medicine & Associate Director, Gastroenterology Fellowship Program Advanced & Interventional Endoscopy Pancreas & Biliary Group

**Specialties:** ERCP, Endoscopic Ultrasound, and Advanced Endoscopy  
**Research:** Translational Research, Ischemic Colitis, Interventions in Gastrointestinal Bleeding, Clinical Trials, and Clinical Outcomes



**Humberto Sifuentes, MD**  
Assistant Professor of Medicine Director, IBD Program

**Specialties:** Crohn's Disease, Ulcerative Colitis, Microscopic Colitis, Pouchitis, Novel Treatment of IBD, Postoperative Crohn's Disease, Constipation and General Gastroenterology  
**Research:** Inflammatory Bowel Disease, Nutrition, Quality Measures, Colon Cancer Prevention



**Brian Francis Lane, MD**  
Associate Professor of Surgery

**Specialties:** Bariatric, Weight Loss, Bariatric Surgery, Minimally Invasive and Digestive Disease Surgery, General Surgery,  
**Research:** Mechanisms of Diabetes and NASH Improvement after Bariatric Surgery, Revision Bariatric Surgery, Total Endoscopic Approaches to Bariatric Surgery, the Application of MIS to Complex Gastrointestinal Procedures



**Sean Michael Lee, MD**  
Assistant Professor of Surgery

**Specialties:** Minimally Invasive and Digestive Disease Surgery, Bariatric Surgery, Weight Loss, General Surgery  
**Research:** Clinical Outcomes of Bariatric Surgery, Metabolic Effects of Bariatric Surgery

Our team is pioneering and conducting cutting-edge research in many areas to uncover new solutions for challenging diseases and to improve digestive health so that we practice tomorrow's medicine today. Some of our current and upcoming clinical trials include: Advanced Endoscopy, Colon, Hepatology Inflammatory Bowel Disease, Motility and Neurogastroenterology. For more information, contact Amanda Schmeltz at 706-721-1968 or Meagan Gibbs at 706-721-1968.

# NEW FACULTY

We are pleased to announce that Dr. Alan Herline has joined our Digestive Health Center team as our first board certified Colon and Rectal Surgeon. In addition to his clinical responsibilities, he is the Harrison Distinguished Chair of Surgery, Vice Chair of Surgery, Associate Director, Digestive Health Center and Section Chief of Minimally Invasive Digestive Disease Surgery.

Previously he was an Associate Professor of Surgery and Biomedical Engineering at Vanderbilt University and led the Colon and Rectal program from its creation to being the busiest surgical program at Vanderbilt as well as the fastest growing and most accomplished Colon and Rectal program in Tennessee.

Dr. Herline is an Engineering graduate from Vanderbilt University and received his medical degree from the Medical College of Georgia in 1994. He completed his Residency in Surgery at Vanderbilt, and specialized in Colon and Rectal Surgery at the Lahey Clinic. He then returned to Vanderbilt to create the Colon and Rectal program.

## Clinical Interests

Dr. Herline is a member of the American Society of Colon and Rectal Surgeons and the New England Colon and Rectal Society. He is a board-certified specialist in the surgical care of disease affecting the colon and the rectum. Dr. Herline is accomplished in minimally invasive procedures, robotic and trans-anal procedures. Dr. Herline's primary surgical interest is in all aspects of colon, rectal disease and treatment, colorectal cancer, inflammatory bowel disease, perianal Crohn's disease, transrectal ultrasound, and laparoscopic surgical approaches.

## Research Interests

In addition to his clinical practice, Dr. Herline has active, funded research projects that combine his engineering and clinical expertise. He speaks nationally, is well published and continues to develop intellectual property in surgical applications.

Dr. Herline is excited about his return to his alma mater, Medical College of Georgia, and looks forward to advancing colon and rectal care in Augusta, the state of Georgia and regionally.



**Dr. Alan Herline**  
Vice Chair, J. Harold Harrison  
Distinguished Chair of Surgery,  
Section Chief of MIDDs,  
Associate Director,  
Digestive Health Center



**Dr. Amol Sharma**  
Assistant Professor of Medicine  
Neurogastroenterology/Motility

We are pleased to announce that Dr. Sharma has joined the Georgia Regents University Department of Medicine as assistant professor in the Section of Neurogastroenterology and GI Motility. He was a resident in internal medicine at Temple University Hospitals in Philadelphia, PA, and a fellow in the Division of Gastroenterology and Hepatology at Penn State Milton S. Hershey Medical Center where he was the chief fellow. He has been recruited to further the Neurogastroenterology/Motility Program at Georgia Regents Health System. Dr. Sharma is board certified in internal medicine.

## Clinical Interests

Dr. Sharma has particular interest in neurogastroenterology & GI motility. During his training, he researched foregut motility disorders and was recognized for his work by the American Neurogastroenterology & Motility Society as a Young Investigator. He looks forward to meeting the challenging needs of our patients in a patient-centered and multidisciplinary manner with the expertise and resources available at the Georgia Regents Digestive Health Center.

## Research Interests

Dr. Sharma's research experience includes achasia, non-obstructive dysphagia, gastroparesis, IBS, chronic constipation and fecal incontinence.



GRHealth officially cut the ribbon on their new state-of-the-art Digestive Health Center April 2015.

Pictured: Dr. Satish Rao with wife Sheila Rao, Jenny Montgomery, Dr. Peter Buckley with wife Leone Buckley.





Communications and Marketing  
1120 15th Street, TR-101  
Augusta, Georgia 30912

Non-Profit  
Organization  
U.S. Postage  
**PAID**  
Augusta, GA  
Permit No. 210

**CHANGE SERVICE REQUESTED**

Wrong address?  
Need to update your information?  
Tell us by email at [updateinfo@gru.edu](mailto:updateinfo@gru.edu)  
Go online to [gru.edu/updateinfo](http://gru.edu/updateinfo)  
Or call us at 706-721-4001

## GRATEFUL PATIENT GIVES BACK

**F**or **Laura Whitty**, it has been a long and winding road from Louisville, Kentucky to Augusta, Georgia. Include pain, frustration and fear in that journey. She has suffered from gastrointestinal issues since her teenage years much like her mother and grandmother. She saw several different physicians in Louisville, Cleveland and Indianapolis, none of whom offered anything more than vague diagnosis of “irritable bowel syndrome”. At each stop, doctors ran the same tests, offered the same prescriptions and got the same results-no relief. Finally, Dr. John Woo recommended that she travel to Georgia to see Dr. Satish Rao. By the time she arrived for her initial visit, her weight had dropped from 130lbs to 98lbs. Her husband began to doubt that she would survive. That was almost three years ago.

Dr. Rao had Laura tested completely differently from previous physicians and was, at last, able to pinpoint her problem-extreme intolerance to high fructose corn syrup as well as dyssynergic constipation. With careful adherence to diet and ?? and treatment, Laura is well on her way to full recovery. She has regained her normal weight and has returned to her passion of gardening, chasing grandchildren and enjoying life in general. While still fighting to overcome lingering issues, Dr. Rao has truly given her a bright future, for which she will be eternally grateful. ●



Laura Whitty

**We hope you will consider supporting our endeavors, so that we can provide the best care for our patients and keep our department on the cutting edge. To learn more about how you can make a gift, please contact David Cantrell at 706-721-1817 or [dcantrell@gru.edu](mailto:dcantrell@gru.edu).**